



International Journal of Indian Medicine

www.ijim.co.in

ISSN: 2582-7634

**Volume - 5, Issue - 1
January 2024**



I J I M

INDEXED



International Journal of Indian Medicine

Access the article online



International Category Code (ICC): ICC-1702 International Journal Address (IJA): IJA.ZONE/258276217634

AYURVEDIC SYSTEMIC MANAGEMENT OF RETINAL HEMORRHAGE IN PROLIFERATIVE DIABETIC RETINOPATHY (PDR): A CASE STUDY

Gadade A.V., Kolachi R.

1. PG Scholar, Department of Shalakyatantra, LKR Ayurvedic College, Gadhinglaj, Kolhapur.
2. Professor, Department of Shalakyatantra, LKR Ayurvedic College, Gadhinglaj, Kolhapur.

ABSTRACT:

Diabetic retinopathy (DR) is a disease leading to visual impairment. It is a micro coagulopathy as an effect of hyperglycemia and other hematological changes in blood vessels. It results into microvascular occlusion, leakage, ischemia and neovascularization. It presents as sudden onset of painless visual loss with blurred vision and also metamorphopsia. Its complications are retinal leakage, edema and vitreoretinal bleeding, leading to poor visual acuity. The patient in the study was having Proliferative Diabetic retinopathy (PDR) with retinal hemorrhage. Symptoms of the patient could be correlated to a *vyadhi* known as *Timira & Raktapitta*. In present study vitiation of *Pitta and kapha* were noted responsible for causing these two. According to *Ashtanga Hrudaya* relevant *doshaghna* drugs with *tikta, kashay rasa* should be used orally for treating the disease. Hence, *vasaguduchyadi kashay, Patoladi gana churna, Tablet chandraprabha guti, Vasa ghrita* and *Sandhaniya Gana Churna* were given to the patient for 4 months. The patient was examined clinically for visual symptoms. Fundus photography was done before & after treatment for evaluation of retinal hemorrhage. The results proved to be significant on the basis of clinical assessment and Fundus photography.

Key words: Diabetic retinopathy, PDR, Retinal hemorrhage

CORRESPONDING AUTHOR:

Dr. Abaso Vinayak Gadade

PG Scholar, Department of Shalakyatantra,
LKR Ayurvedic College, Gadhinglaj, Kolhapur

Contact No. : 9923164000 Email: abasahebgadade@yahoo.in

How to cite this article: Gadade A.V., Kolachi R. Ayurvedic Systemic Management of Retinal Haemorrhage in Proliferative Diabetic Retinopathy (PDR): A Case Study. Int J Ind Med 2024;5(1):25-30 DOI: <http://doi.org/10.55552/IJIM.2024.5104>

Introduction:

Diabetic retinopathy (DR) is a disease leading to visual impairment. It is a micro coagulopathy as an effect of hyperglycemia and other haematological changes in Diabetes. It results into microvascular occlusion, leakage, ischemia and neovascularisation. In Proliferative Diabetic retinopathy (PDR) hypoxic retinal tissue releases angiogenic growth factors (like vascular endothelial growth factor - VEGF) ultimately leading to neovascularization on disc or elsewhere on retina. It usually complicates into retinal or vitreous haemorrhage or retinal detachment. If the Macula is included in the lesion, visual loss is severe [1]. Commonest symptoms of this condition are blurred or suddenly diminished vision. The diagnostic tools commonly used are Fundus photography, Ocular Coherence Tomography (OCT) and Fundus Fluorescein Angiography (FFA). First line of treatment for PDR is intravitreal injection of anti-vascular endothelial growth factor (VEGF) drugs, including bevacizumab, ranibizumab, and aflibercept. But these drugs at times show temporary or no improvement in vision. Other treatment opted are steroid intravitreal injections, Pan retinal photocoagulation (PRP) and vitrectomy (in case of haemorrhage or retinal detachment). But all these treatment modalities have poor prognosis in long run and prevent only 50 % of vision loss [2].

This calls for alternative remedial solutions in such cases. In classics of Ayurveda, *Sushruta Samhita* a disease with visual impairment is described as Timira in which distortion of image, blurred or diminished vision, low near

vision are the presenting symptoms. Timira (prathama and dwiteeya patalagatha) a Sadhya, Drishtigata roga[3] is described by almost all the Ayurvedaacharyas in their texts. Triteeya patalagatha Timira difficult to treat in which Blurred vision, patchy vision loss, floaters in front of eyes, or severe vision loss^[4]are its symptoms. In *Ashtanga Hrudaya*, a classic of Ayurveda, there is detailed description of the disease *Raktapitta* (bleeding through external orifices)^[5]. In this disease *rakta vaha srotas* is primarily involved. *Urdhwaga raktapitta* is the condition in which there is a bleeding through the upper orifices (nose, eye, ear or oral cavity)^[5]. In this type, *pitta* is the primary *dosha* along with *kapha* as *anubandha dosha*. It is said to be easily curable^[5]. *Pittashaman* drugs with *tikta*, *kashay rasa* have been indicated as used for treating *urdhwaga Raktapitta*.^[5]

Aims and Objectives:

1. To explore pathogenesis of PDR and Retinal haemorrhage in Ayurvedic terms
2. To evaluate the effect of drugs indicated for *timira* as well as other drugs not mentioned in *timir chikitsa* on Retinal haemorrhage.

Materials and methods:

Case history: A 35 year old female patient (known diabetic & hypertensive) came to outpatient department for diminished and blurred vision of both eyes (right eye <6/60, n/- and <6/60 n/- with glasses & left eye <6/60p, n/36 and 6/60, n/24 with glasses). She had sudden onset of these symptoms in the last 2 weeks. Fundus photography of right eye (done on 6/6/23): Showed retinal

haemorrhage surrounding macula and left eye showed hazy fundus. She was previously diagnosed as PDR.

Previous Treatment: Patient was prescribed intra ocular Avastin injection. But she was not willing for injection hence, she sought for Ayurvedic treatment.

Food habit: regular intake of fermented and maida , rice and black gram based food (*madhur and abhishyandi*) along with spicy (*katu rasatmak food*).

Examination (done on 08/06/23):

Visual Acuity of Right Eye: Finger counting on 8 feet <6/60, n/- Finger counting on 9 feet <6/60 n/- with glasses

Visual Acuity of left eye : Finger counting on 8 feet <6/60p, n/36 6/60, n/24 with glasses

Both eye Anterior segment normal Fundoscopy of right eye retinal haemorrhage surrounding macula and left eye showed hazy fundus.

Naadi : Pittapradhan

Pathogenesis: ^[3,5]

Hetusevan (katu, ushna aahar, madhur and abhishyandi) → pitta kapha prakopa kledavruddhi

Purvarup: blurred vision.

Rup: diminished and distorted vision.

Dosh and Dushya: Pitta and Kapha

Sthan: Both Eyes

Nidaan: Timira with Raktapitta

Treatment given

1. Tablet *Chandraprabha guti* 250mg Bid ^[6]
2. *Vasaguduchyadi kashay* 40 ml in morning with honey ^[7]
3. *Patoladi gana churna* 5 gm in morning ^[8]
4. *Vasa ghrita* 10gm in morning ^[9]
5. *Sandhaniya Gana Churna* 5gm at bedtime. ^[10]

Medicines were given to the patient for 4months and follow up was taken every month.

Observations and result:

Visual Acuity: The vision showed marked improvement for distant and near objects. [Table 1&2]

Table 1: Visual acuity of Right eye during treatment period

Acuity of vision of Right eye	Without glasses	With glasses
08/06/23	<6/60 n/-	<6/60 n/-
12/07/23	<6/60 n/36	<6/60 n/36
17/08/23	<6/60 n/36	6/60 n/12
25/9/23	6/36 n/18	6/9 n/6

Table 2: Visual acuity of Left eye during the treatment

Acuity of vision of Left eye	Without glasses	With glasses
-------------------------------------	-----------------	--------------

08/06/23	<6/60 n/36	6/60 n/24
12/07/23	6/60 n/36	6/60 n/10
17/08/23	6/60 n/36	6/12 n/8
25/9/23	6/60 n/18	6/12 n/6

Retina was evaluated by Fundus Photograph which was done before and after treatment.[image 1-2]

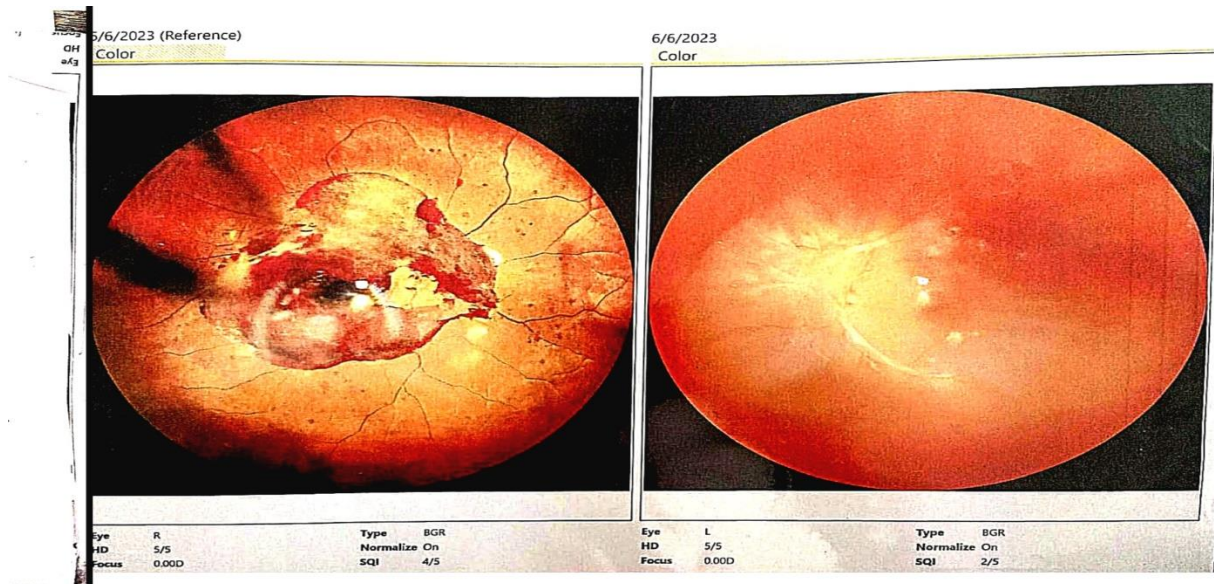


Image 1: Fundus photograph dated 06/06/223 showing retinal hemorrhage

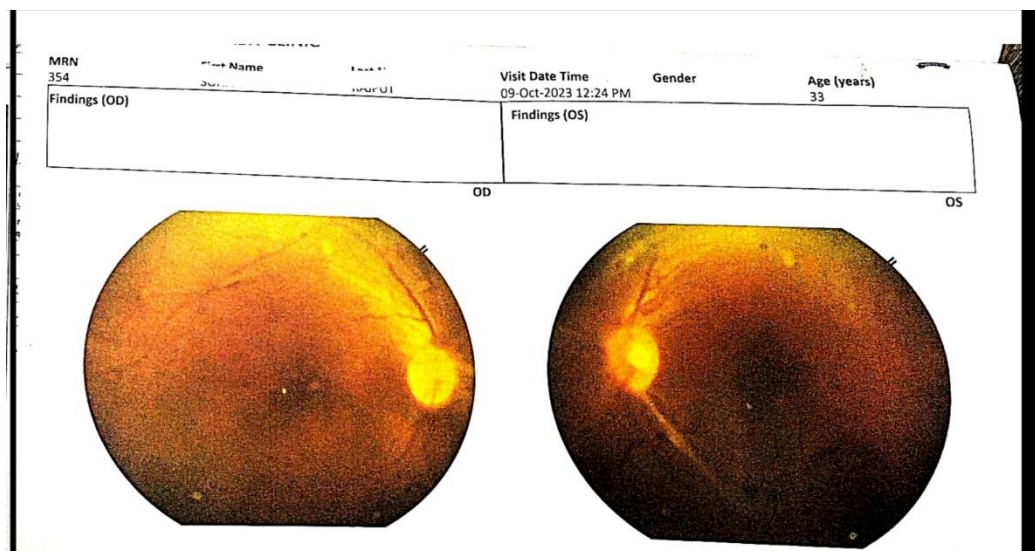


Image 2 : Fundus photograph .dated 09/10/23 eye showing normal structure of macula. The retinal hemorrhage was completely resolved after the treatment.

Discussion:

Discussion

The condition with which the patient in the study presented, was comparable to *Timira & Raktapitta*. Line of treatment for treating both diseases was decided according to involved *Doshas*. *Pitta kapha shaman* drugs with *tikta, kashay rasa* were used. Though there are variety of medicines controlling pitta, a combination of commonly used medicines was used for the treatment.

1. Tablet *Chandraprabha guti* 250mg Bid^[6]
2. *Vasaguduchyadi kashay* 40 ml in morning with honey^[7]
3. *Patoladi gana churna* 5 gm in morning^[8]
4. *Vasa ghrita* 10gm in morning^[9]
5. *Sandhaniya Gana Churna* 5gm at bedtime.^[10]

The probable action of the medicines was as follows,

The *Chandraprabha guti* is having *kledaghna, kapha pittahara pramehaghna* properties and is indicated in diseases of eye by *Sharangdhara*.^[6]

The *vasaguduchyadi kashay* has herbs of *tikta and kashay rasa* with *pittakaphaprashaman* properties. It is indicated for treating *pandurog, raktapitta and kamala*^[7]. *Patoladi gana* also has *tikta and kashay rasa* and reduces *pitta & kapha*^[8]. *Vasa ghrita*^[9] is indicated in *Raktapitta chikitsa*. It is also indicated in *Timira*. It contains *pittahara dravyas with tikta, kashaya rasa* has properties which help to arrest the bleeding. *Sandhaneeya gana* is described by *Charakacharya*. It is also having *tikta kashay rasatmak* herbs which reduce *pitta & kapha*.

^[10] The *Sandhan* action is defined by Acharya

Sushrut as one of the measures to stop bleeding.^[11] This explains the efficacy of the medicines in management of retinal hemorrhage in PDR. The medicines are efficient to cure the *timira* in form of PDR.

Conclusion:

PDR with retinal hemorrhage can be compared with a disease of *timira* along with *raktapitta*. The medicines indicated for *raktapitta* helped significantly in treatment of retinal hemorrhage along with the medicines chosen according the involved doshas. *Vasa Ghrit* was helpful for treating both *Timira & Raktapitta*. The patient had significant improvement in visual acuity with symptomatic relief. In addition retinal hemorrhage was completely resolved as noted in Fundus photograph. However, the pharmacological action and pharmacodynamics of these medicines on the retinal blood vessels, macular area and retinal layers needs further study.

One can conclude from this study that ophthalmic disorders need not be treated just with local medications but also use of only systemic medicines can also be beneficial in eye diseases. This study proves that when the diagnosis of the disease and the treatment of the disease, both are done on the basis of Ayurvedic principles, the results ought to be positive.

References:

1. Jack J Kanski, Clinical Ophthalmology: a systematic approach. Elsevier Health Sciences Sixth edition, page no. 566-578
2. Flaxel CJ, Adelman RA, Bailey ST, Fawzi A, Lim JI, Vemulakonda GA, Ying GS (January 2020). "Diabetic

- Retinopathy Preferred Practice Pattern"Ophthalmology. 127 (1) P66 – P145
3. Yadavaji Trikamaji(editor).
Commentary:
Nibandhasangraha of Dalhana on Sushruta Samhita of Sushruta, Uttarantra, Chapter 7, verse no.6-7, 8th edition, Varanasi: Chaukhambha Orientalia; 2005:606
 4. Yadavaji Trikamaji(editor).
Commentary:
Nibandhasangraha of Dalhana on Sushruta Samhita of Sushruta, Uttarantra, Chapter 7, verse no.10, 8th edition, Varanasi: Chaukhambha Orientalia; 2005:606
 5. Garde GK, Editor, Sartha Vagbhat (Ashtang Hruday), Nidansthan, adhyay 3, verse 2-10, 14, 8th Edition, Raghuvanshi Prakashan, 1996, p.308.
 6. Sharangdhara, sharangdhara samhita, Gutika kalpana, translated by Prof.Srikanta urthy, 2nd edition: Chaukhambha Orientalia, shloka 40 - 49.p.105 – 6
 7. Garde GK, Editor, Sartha Vagbhat (Ashtang Hruday), chikitsasthan, adhyay 16, verse 13, 8th Edition, Raghuvanshi Prakashan, 1996, p.308.
 8. Garde GK, Editor, Sartha Vagbhat (Ashtang Hruday), sutrasthan, adhyay 15, verse 15, 8th Edition, Raghuvanshi Prakashan, 1996, p.67
 9. Garde GK, Editor, Sartha Vagbhat (Ashtang Hruday), chikitsasthan, adhyay 2, verse 42-44, 8th Edition, Raghuvanshi Prakashan, 1996, p.230
 10. Acharya Vidyadhar Shukla, Charakasamhita of Agnivesha , Shadvirechanshatashritiyaadhaya Chapter 4 verses 5 of Sutrasthana, Edition reprinted 2019, New Delhi ChaukhambaPublications, page no 72
 11. Yadavaji Trikamaji(editor).
Commentary:
Nibandhasangraha of Dalhana on Sushruta Samhita of Sushruta, Sutrasthan, Chapter 14, verse no.39, 8th edition, Varanasi: Chaukhambha Orientalia; 2005: 606

Source of Support: None declared

Conflict of interest: Nil

© 2024 IJIM (International Journal of Indian Medicine) |

An Official Publication of ARCA- AYURVEDA RESEARCH & CAREER ACADEMY

Website: www.ijim.co.in Email: ijimjournal1@gmail.com