International Journal of Indian Medicine

www.ijim.co.in

ISSN: 2582-7634

Volume - 7, Issue - 01

January 2026



IJIM

INDEXED

Case Report

eISSN : 2582 - 7634

International Journal of Indian Medicine, 2026; 7(01):01-08 ISSN: 2582-7634

International Journal of Indian Medicine

International Category Code (ICC): ICC-1702 International Journal Address (IJA): IJA.ZONE/258276217634

Ayurvedic Intervention in Abducent Nerve Palsy secondary to Mononeuritis Multiplex: A Case Report.

Virkar S.[1], Khurana B.[2], Jagtap P.[3], Virkar C.[4]

1. Assistant Professor, Dept of Shalakya Tantra, PDEA's College of Ayurved & Research Centre, Nigdi, Pune, Maharashtra 411044.
2. Research Associate, Department of Translational Research, All India Institute of Ayurveda, New Delhi – 110076.
3. Professor & HOD, Dept. of Shalakya Tantra, Dr. D. Y. Patil College of Ayurved and Research Centre, Dr. D.Y. Patil Vidyapeeth (Deemed to be University) Pune- 411018 Maharashtra, India.
4. Professor & HOD, Dept of Shalakya Tantra, PDEA's College of Ayurved & Research Centre, Nigdi, Pune, Maharashtra 411044.

ABSTRACT: Abducent (sixth cranial) nerve results in lateral rectus muscle contraction. When palsy of this nerve occurs symptoms like diplopia, esotropia and limitation of abduction of affected side observed. Mononeuritis Multiplex is commonly associated with diabetes mellitus where asymmetrical, asynchronous, painful peripheral neuropathy develops. Damage to abducent nerve along with peripheral neuropathy results in hindrance of patient's routine and eyesight. According to ayurveda, diplopia can be correlated with patalagata dosha dushti and can be treated like timira chikitsa. **Objective**: To rescue patient's vision and provide symptomatic relief by ayurvedic intervention in left abducent nerve palsy which developed secondary to mononeuritis multiplex. **Material and Method**: 62 year old female patient, visited shalakyatantra OPD on 15th November 2023, with symptoms like horizontal diplopia, limitation of abduction of left eye and mild esotropia in primary gaze and floaters since 2 months, known systemic history of diabetes mellitus since 11 years, hypertension since 7 years and mononeuritis multiplex since 6 months. Other associated symptoms were bilateral foot drop due to damage of nerves in lower limb. Ayurvedic treatment like deepana, pachana, anulomana along with vata shamaka, chakshushya medication with local treatments like kriyakalpa are advised. **Result**: Marked symptomatic relief on subjective as well as objective parameters were noted. Abduction of left eye improved along with reduced diplopia and resolved esotropia. Quality of life of patient improved. **Discussion**: Ayurvedic intervention in abducent nerve palsy secondary to mononeuritis multiplex offers a promising alternative for significant relief in symptoms, improvement in abduction of affected eye and control the recurrence.

KEYWORDS: Abducent nerve palsy, Ayurvedic intervention, Mononeuritis multiplex, Jinmha Vikara, patalagata dosha dushti.

CORRESPONDING AUTHOR:

Dr. Sanika Abhay Virkar

Assistant Professor, Dept of Shalakya Tantra, PDEA's College of Ayurved & Research Centre, Nigdi, Pune, Maharashtra 411044.

Email- dr.sanikaabhayvirkar@gmail.com

How to cite this article: Virkar S., Khurana B., Jagtap P., Virkar C. Ayurvedic Intervention in Abducent Nerve Palsy secondary to Mononeuritis Multiplex: A Case Report. Int J Ind Med 2026;7(01):01-08

DOI: http://doi.org/10.55552/IJIM.2026.70101

eISSN : 2582 - 7634

International Journal of Indian Medicine, 2026; 7(01):01-08 ISSN: 2582-7634

INTRODUCTION:

Abducent nerve lies at the mid-level of pons, ventral to the floor of fourth ventricle. The fibres leave the brain stem ventrally at Ponto medullary junction.[1] Abducent (sixth cranial) nerve results in lateral rectus muscle contraction. When palsy of this nerve occurs symptoms like diplopia, esotropia and limitation of abduction of affected side observed. Microvascular ischemia due to systemic diseases like diabetes mellitus and hypertension can result in abducent nerve palsy. In this condition complete or incomplete paralysis of lateral rectus muscle of eye leads to ocular deviation. Mononeuritis Multiplex is commonly associated with diabetes mellitus where asymmetrical, asynchronous, painful peripheral neuropathy develops. Damage to abducent nerve along with peripheral neuropathy results in hindrance of patient's routine and eyesight.

One of the cause of abducent nerve palsy is systemic conditions like diabetes mellitus since many years may result in condition like mononeuritis multiplex which leads to damage of abducent nerve and peripheral neuropathy. Symptoms of abducent nerve palsy are horizontal diplopia which worsens while looking in the direction of affected eye, diplopia increases for distance than near (D > N). Esotropia of affected eye in primary gaze. Limitation of abduction of affected eye and compensatory face turn towards the affected eye. Visual acuity may or may not be reduced.[2] According to ayurveda, this condition can be correlated with vataj nanatmaja vikara; jinmha & diplopia can be correlated with patalagata dosha dushti and can be treated like timira chikitsa. Acharya Sushruta explained trutiya patalagata dosha dushti and vagbhatacharya explained dwitiya patalagata dosha dushti. Symptoms can be correlated with timira and treated accordingly. Prameha janya timir vyadhi lakshana like vihwal drushti, makshika mashaka kesha jala paslıyati, tamasa darshana and nasa akshi yuktani viparitani vikshate are observed.[3] Nerve palsy can be clinically correlated with vata vyadhi lakshana like ardita and vata hara chikitsa can be given to the patient. Modern treatment modalities offer occlusion therapy, prism correction, botulinum toxin injection and surgical transposition of muscle.[4] These treatments are expensive and having side effects. So developing ayurvedic treatment protocol as an alternative is necessary. Ayurvedic treatment aims on encountering disease pathogenesis from the root.

Aims and Objective:

This case report aims at developing ayurvedic treatment protocol to treat left abducent nerve palsy developed secondary to mononeuritis multiplex. Objective of this case report is to study the mode of action and potential role of ayurvedic therapeutics in treatment of trutiya patalagata dosha dushti (timira)

Chief complaints:

A 62 year old female patient; visited shalakya tantra OPD on 15th November 2023 with complaints of horizontal diplopia, limitation of abduction of left eye and mild esotropia in primary gaze and floaters since 2 months, known systemic history of diabetes mellitus since 11 years, hypertension since 7 years and mononeuritis multiplex since 6 months. Other associated symptoms were bilateral foot drop due to damage of nerves in lower limb. No history of trauma, stroke or recent travel.

Past History: History of Diabetes mellitus since 11 years. Hypertension since 7 years and mononeuritis multiplex since 6 months. Patient is on regular medication for the same.

Drug History: patient is on regular medication for diabetes mellitus Rx: Glimital M tablet SR 1BD. Tablet Amlo 5 1OD for hypertensive management. Tablet Nutrolin B Plus 1BD and Tablet Juviana plus 1HS as

eISSN : 2582 - 7634

International Journal of Indian Medicine, 2026; 7(01):01-08 ISSN: 2582-7634

treatment of mononeuritis multiplex. No history of any drug allergy known till date. **Family History:** Paternal history-diabetes mellitus, which could be a potential factor for contributing patient's condition. **Past surgical History:** Right eye cataract surgery 9 years ago, left eye operated for cataract 3 years ago.

Ashtavidha Pariksha: •Nadi: 88/min •Mala: samyak •Mutra: 5-6 times/day •Jivha: Sama. •Shabda: samyaka • Sparsha: Anushnasheeta • Druk: Vikruti • Akruti: Madhyam

Ocular Examinations:

Table 1: Visual acuity for distant and near

Distant vision	**Right eye**	**Left eye**
Without glasses	6/9	6/18 P (Diplopia)
With glasses	6/6 P	6/18 (Diplopia)
Pinhole improvement	6/6 P	6/12 P
Near vision	**Right eye**	**Left eye**
Without glasses	N8	N8
Without glasses	N6	N6

Table 2: slit lamp bio microscopic examination

Ocular examination	**Right eye**	**Left eye**
Eye lid	Normal in size, shape Without any anomaly	Normal in size, shape Without any anomaly
Conjunctiva	Normal without any papillae, follicles or concretions	Normal without any papillae, follicles or concretions
Cornea	Normal curvature and sheen	Normal curvature and sheen Hirschberg test corneal light reflected near temporal pupillary margin.
Sclera	Normal	Normal
Anterior chamber	Normal in depth without any cells or flares	Normal in depth without any cells or flares
Iris	Normal, brown in colour	Normal, brown in colour
Pupil	Round regular reactive to light	Round regular reactive to light
Lens	Pseudophakia PCIOL stable	Pseudophakia PCIOL stable

Table 3: Extra ocular movements (EOM) for ocular motility examination

	Right eye	**Left eye**
Above (superior)	normal	normal
Below (inferior)	normal	normal
Medial (nasal)	normal	Eso deviation
Lateral (temporal)	Normal Slight diplopia	Restricted abduction Diplopia worsened

Table 4: Worth 4 dots test

Right eye	**Left eye**
Normal	6 dots noted indicating Diplopia

eISSN : 2582 - 7634

International Journal of Indian Medicine, 2026; 7(01):01-08 ISSN: 2582-7634

Table 5: fundoscopic examination

Fundus Examination	**Right eye**	**Left eye**
Pupil dilatation	8 mm	8 mm
Media	Pseudophakia	Pseudophakia
Cup disc ratio Shape Margin Neuro retinal rim	0.3:1 Normal, papilledema ruled out Clear Within normal limit (WNL)	0.3:1 Normal, papilledema ruled out Clear Within normal limit (WNL)
Macula	Dull	Dull
Foveal reflex	Present, fixation normal	Present, fixation normal
Vessels	Micro aneurysm	Micro aneurysm
Other findings	Moderate non proliferative diabetic retinopathy (NPDR)	Moderate non proliferative diabetic retinopathy (NPDR)

Table 6: other examinations

Examination	**Right eye**	**Left eye**
Intra ocular pressure (IOP)	17.3 mmHg	21 mmHg
Sac syringing	Patent	Patent

Diagnostic Assessment

Patient was advised to investigate Complete blood Count (CBC), Blood Sugar Level (BSL), MRI (brain and orbit) and 2D Echo was advised. In CBC reports, Erythrocytes Sedimentation Rate (ESR) was raised. BSL fasting and post prandial were raised hence hbA1C was advised. MRI reports ruled out space occupying lesion, vestibular schwannoma and pituitary adenoma. Ejection fraction was 60% in 2D Echo with mild tachycardia.

History of systemic metabolic disorder of diabetes mellitus, hypertension and mononeuritis multiplex with chief complaints like diplopia, lateral rectus restricted movement in left eye were clearly suggestive of left abducent nerve palsy. Ocular examination and laboratory investigation confirmed the diagnosis. No challenges were faced to confirm the diagnosis.

Ayurvedic therapeutic intervention Patient was advised dietary modulation to control diabetes mellitus and hypertension. Administration of nidana parivarjana.[5] (avoiding disease causing factors) like lifestyle modification, following a balance diet, regular exercise along with medication to control systemic metabolic disorders in association with panchakarma and local treatment like kriyakalpa contributed to manage the disease prognosis.

Ayurvedic treatment like deepana, pachana, anulomana along with vata shamaka, chakshushya medication with local treatments like kriyakalpa are advised. Prameha hara internal medication along with shodhana (purfication) with panchakarma and kriyakalpa (local treatment) nourishes capillaries like sira, reduces shotha and enables self maintenance of system. Samanya chikitsa of timira mentioned as-[6]

Detailed ayurvedic treatment plan given is mentioned in table 9.

eISSN : 2582 - 7634

International Journal of Indian Medicine, 2026; 7(01):01-08 ISSN: 2582-7634

Table 7: Ayurvedic therapeutic intervention with duration and dosage

Date of visit	Treatment	Medication	Dosage	Duration
15/11/2023	Deepana (Appetites digestive fire)	Musta shunthi kwatha	Kwatha prepared with 10 gm musta and 5 gm shunthi in 2.5 lit water. Reduced to 2 lit and consumed in a day.	3 days
	Pachana (Digestive medicine)	Amapachaka vati	2 BD	3 days
	Anulomana (Purgative and carminative)	Avipattikara churna	3 gm HS with lukewarm water	3 days
18/11/2023	Vata shamaka (Alleviates vata)	Capsule Palsinuron[7]	2BD with lukewarm water	1 month
	Prameha hara (Anti diabetic)	Mehantaka vati	2 BD	1 month
		Nishakatakadi kashaya	15 ml BD along with lukewarm water	1 month
	Kriyakalpa (Local treatment)	Netra dhavana- triphaladi kashaya Netra tarpana- jeevantyadi ghrita Pinda sweda- shali shashti Nasya- panchendriya vardhak taila	Once a day in kriyakalpa unit	7 days
	Viddha karma[8]	Vedhan karma with 26 and halfinch needle at apanga, lalata and upanasika points		Alternate day 3 sittings.
25/11/2023	Chakshyshya (Rejuvenates eyes) Symptomatic relief was observed.	Saptamruta lauha[9]	1 OD	15 days
23/12/2023	Visual acuity improved. Diplopia reduced. Left eye abduction improved. Symptomatic relief achieved.			

eISSN : 2582 - 7634

International Journal of Indian Medicine, 2026; 7(01):01-08 ISSN: 2582-7634

Result

Ayurvedic therapeutic intervention was administered for one month. Marked visual improvement with symptomatic relief and overall well being resulted in elimination of diplopia and abduction of left lateral rectus improved.

Follow up after 1 month revealed no recurrence of any symptom.

Result was obtained by assessment of subjective and objective criteria before treatment and after treatment as mentioned in table 8.

Table 8: Assessment criteria of left eye

Symptom	**Before treatment**	**After treatment**
Diminish vision	Severe	Mild
Visual acuity Distant Distant with glasses Near with glasses	 6/18P 6/18 N8	 6/18 6/9 P N6
Floaters in left eye	Present	Occasional
Abduction of left lateral rectus	Absent	Improved
Diplopia	Severe	Absent
Images		

DISCUSSION:

Ayurvedic treatment was given for 1 month regularly and follow up was taken in the month of December. By understanding pathogenesis of disease; reversal of pathology by ayurvedic treatment achieved. Strength of this article is images were taken before treatment and after treatment which depicts marked improvement in left abducent nerve palsy. All the subjective and objective assessment criteria contribute to resolution of abducent nerve palsy in left eye. Root cause of this condition is metabolic diseases like diabetes mellitus, hypertension and mononeuritis multiplex. This systemic disease was well treated by lifestyle modification, dietary modulation along with regular exercise and medication.

eISSN : 2582 - 7634

International Journal of Indian Medicine, 2026; 7(01):01-08 ISSN: 2582-7634

• Pathogenesis of mononeuritis multiplex-[10]

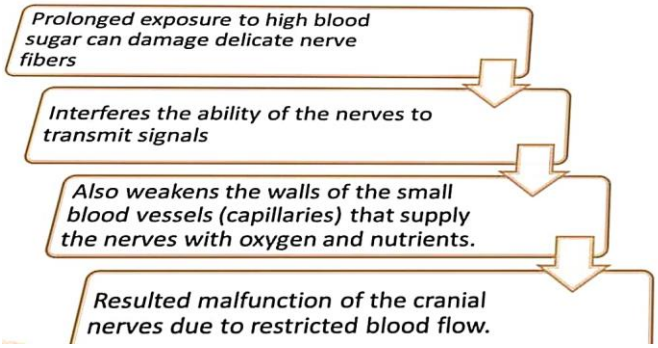

• Pathogenesis of abducent nerve palsy-[11]

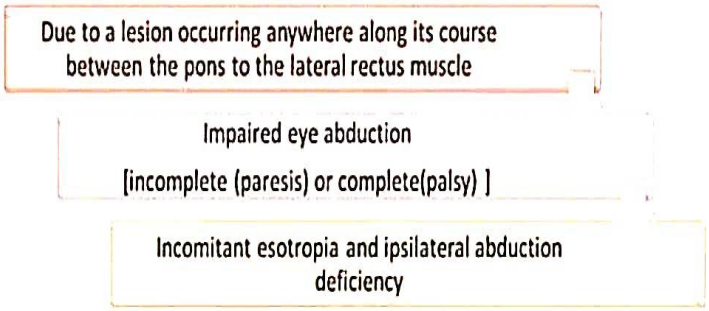

• Mode of action according to ayurveda-

Vitiated vata along with tridosha causes timira netra roga. Considering disease pathogenesis vata hara, prameha hara, tridosha shamana, rasayana and chakshushya treatment is prescribed.

Table 11: pharmacological action of ayurvedic medication

Medication	**Pharmacological action**
Musta shunthi kwatha	Ignites the dhatvagni (digestive fire)
Amapachaka vati	Digestion of ama (digestion of toxins)
Avipattikara churna	Anulomana (purgative)
Mehantaka vati	Prameha hara (anti diabetic)
Nishakatakadi kashaya	Prameha hara (anti diabetic)
Saptamruta lauha	Chakshushya rasayana (eye rejuvenation)
Capsule palsinuron	Vata shamaka (alleviates vata dosha), acts on CNS and neuro protective.

CONCLUSION:

Timely intervention to prevent further loss by ayurvedic treatment was achieved. Root cause of disease was well treated by ayurvedic treatment. Marked improvement in visual acuity with reduction in clinical symptoms were noticed within period of one month. Further complications were prevented. However further studies should be carried out to establish potential ayurvedic treatment protocol for management of abducent nerve palsy secondary to mononeuritis multiplex.

Informed written consent

Informed written consent was taken from patient for publication of case report. It is made available for verification by editor of journal.

Author contribution

All authors have equally contributed in treating this patient, documentation work and development of manuscript.

Conflict of interest

To the best of our knowledge; all authors declare that this study was carried out in absence of any reason that could create potential conflict of interest.

Source of funding

None.

REFERENCES:

1. A K Khurana, comprehensive ophthalmology, 5th edition. New age international (P) ltd. Reprint 2014 P-275.
2. Oshitari T. The pathogenesis and therapeutic approaches of diabetic neuropathy in the retina. Int J Mol Sci (2021) 22:9050. Doi: 10.3390/ijms22169050
3. Paradakara HS. Astanga hridaya of vagbhatta, uttarsthana. 9th Ed. Ch.12 vers 10 Varanasi: Chaukhamba Orientalia publication; 2010 P. 817,157.
4. Shrader EC, Schlezinger NS. Neuro-ophthalmologic evaluation of abducens nerve paralysis. Arch Ophthalmol. 1960;63:84–91.
5. Shastri A Editor, Hindi commentary ayurveda tattva sandipika, sushruta samhita uttar tantra, drishtirogavigyaniya,sVaranasi: Chaukhamba Orientalia publication; 2016 P 41.
6. Kaviraj Ambika Datta Shastri, Shushruta Samhita Uttaratantra 7/19, Chaukhamba Sanskrit Sansthan, Varanasi, Edition Reprint 2014, Page no.11
7. Shastri Pt.Kashinath and Chaturvedi Gorakhnath, Charaka Samhita, reprint 2008, Varanasi, Chaukhambha Bharti Academy, Sutra Sthana chap 14/2024, pg.no.286
8. Krishnan V, Pillai G, editors, viddha karma 26th ed. Kerala: Vidyarambham Publishers; 2006. P. 337.
9. Galetta SL, Smith JL. Chronic isolated sixth nerve palsies. Arch Neurol. 1989;46:79
10. Von Noorden GK, Campos EC. Binocular vision and ocular motility. 6th ed. New York: Mosby; 2002.
11. Lee AG, Eggenberger E, Golnik K, Miller NR. MRI in isolated sixth nerve palsies. Neuroradiology. 2002;44:711–712.

Source of Support: None declared

Conflict of interest: Nil

© 2026 IJIM (International Journal of Indian Medicine) |

An Official Publication of ARCA- AYURVEDA RESEARCH & CAREER ACADEMY

Website: www.ijim.co.in **Email**: ijimjournal1@gmail.com