



# International Journal of Indian Medicine

[www.ijim.co.in](http://www.ijim.co.in)

**ISSN: 2582-7634**

**Volume - 5, Issue - 4**

**April 2024**




# IJIM

INDEXED



# International Journal of Indian Medicine



International Category Code (ICC): ICC-1702

International Journal Address (IJA): IJA.ZONE/258276217634

## MANAGEMENT OF NON-SPECIFIC ORBITAL INFLAMMATION USING HARIDRADI BIDALAKA- A CASE REPORT.

Gorakh A. P.<sup>1</sup> Dakhore J<sup>2</sup>

1. PG Scholar, Shalakyatantra Department, Vidarbha Ayurveda Mahavidyalaya, Amravati
2. Guide and HOD Shalakyatantra Department, Vidarbha Ayurveda Mahavidyalaya, Amravati

**ABSTRACT:** Idiopathic orbital inflammatory disease (IOID), also called non-specific orbital inflammation (NSOI) or orbital pseudotumor, is an uncommon disorder characterized by non-neoplastic, non-infective, space-occupying orbital infiltration with inflammatory features. The process may preferentially involve any or all of the orbital soft tissues. Histopathological analysis reveals pleomorphic inflammatory cellular infiltration followed by reactive fibrosis. Unilateral disease is typical in adults, although in children bilateral involvement may occur. Intracranial extension is rare. Simultaneous orbital and sinus involvement is also rare and may be a distinct entity [1]. According to Ayurveda, this inflammatory condition on the eye lids can be correlated with Kaphaja Netra Abhishyanda and treated accordingly. Kaphaja Netra Abhishyanda is defined in Ayurveda as a disease affecting all parts of the eye characterised by Guruta (heaviness of lids), Kandu (itching), Pichila (repeated lacrimation), Alpa Vedana (Foreign body sensation) photophobia and burning sensation in eyes etc. An ocular therapeutic called Bidalaka is the application of medicated paste on the eye's outer surface expect eye lashes. Bidalaka is indicated in inflammatory conditions of the eyes. A 72-year-old female patient diagnosed with NSOI on clinical presentation was advised Haridradi Bidalaka for five days. The signs & symptoms were reduced to a very mild degree. The result proved to be effective based on clinical assessment.

**KEYWORDS:** Idiopathic orbital inflammatory disease (IOID), Non-specific orbital inflammation (NSOI), Extraocular muscles, lacrimal gland, cavernous sinus, thyroid eye disease, orbital lymphoma, Kaphaja Netra Abhishyanda, Bidalaka.

### CORRESPONDING AUTHOR:

**Dr.Aakansha Pradip Gorakh**

PG Scholar, Shalakyatantra Department,  
Vidarbha Ayurveda Mahavidyalaya, Amravati

**How to cite this article:** Gorakh A. P., Dakhore J. Management of non-specific orbital inflammation using haridradi bidalaka- a case report. Int J Ind Med 2024;5(4):01-05 DOI: <http://doi.org/10.55552/IJIM.2024.5401>

**INTRODUCTION:**

**Clinical Presentation:** All patients with suspected NSOI require a full ophthalmic assessment/workup. NSOI is typically characterized by the abrupt onset of pain, proptosis and other orbital inflammatory signs such as swelling and erythema. Unilateral presentation is more typical but bilateral presentations are not uncommon. Pediatric NSOI differs from the adult presentation and is more commonly characterized by bilateral manifestation, uveitis, disc edema and eosinophilia. Pain is the most common symptom in adult NSOI and occurs 58-69% of the time followed by diplopia (31-38%). Periorbital edema/swelling is the most common sign and occurs 75-79.2% of the time (figure) followed by proptosis (32-62.5%), EOM restriction (54.2%) red eye (48%), chemosis (29%), decreased vision (20.8%), and ptosis (16.7%).<sup>34-35</sup> Therefore, physical examination of patients with suspected NSOI involves lid assessment (retraction/lid lag/lagophthalmos), orbital assessment (proptosis), extraocular muscles (restriction), globe (injection/chemosis), and optic nerve function (visual acuity/color plates/relative afferent pupillary defect). Because of the association between rheumatologic disease and NSOI the typical laboratory work-up for suspected NSOI should include a complete blood count, basic metabolic panel, thyroid function studies, erythrocyte sedimentation rate, antinuclear antibodies, antineutrophil cytoplasmic antibodies, angiotensin-converting enzyme level, rapid plasma reagin test, and rheumatoid factor. Additionally, infectious etiologies including syphilis and tuberculosis should be ruled out <sup>[2]</sup>.

**DIAGNOSIS:**

**Symptoms** typically consist of acute or subacute ocular and periocular redness, swelling and pain. Systemic symptoms are

common in children.

**Signs**-Pyrexia is present in up to 50% of children, but is rare in adults. Congestive proptosis.

Mild to severe ophthalmoplegia may occur.

Features of optic nerve dysfunction, particularly if the inflammation involves the posterior orbit. There may be optic disc swelling.

Choroidal folds, if present, may be associated with reduced vision but optic neuropathy must always be suspected.

**Course.** The natural history of the inflammatory process is very variable. Spontaneous remission after a few weeks without sequelae. Intermittent episodes of activity, usually with eventual remission. Severe prolonged inflammation eventually leading to progressive fibrosis of orbital tissues, resulting in a 'frozen orbit' characterized by ophthalmoplegia, which may be associated with ptosis and visual impairment caused by optic nerve involvement.

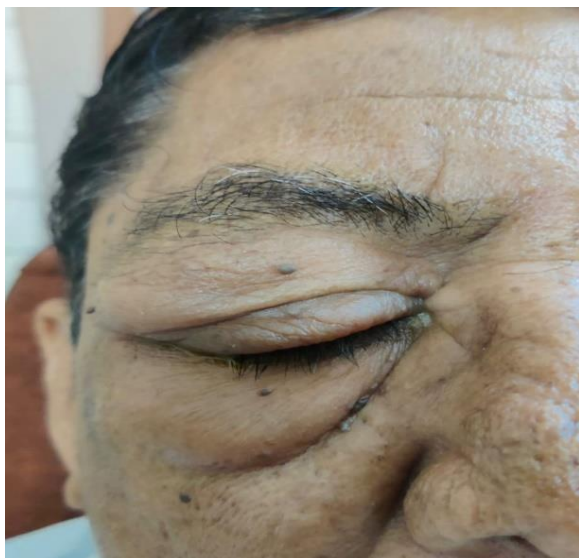**Investigation:** CT shows ill-defined orbital opacification and loss of definition of contents.

Biopsy is generally required in persistent cases to confirm the diagnosis and particularly to rule out neoplasia and systemic inflammatory conditions. A wide range of other investigations may be considered to aid in the exclusion of alternative diagnoses, particularly infection, lymphoma and non-neoplastic infiltrative disorders such as sarcoidosis and Wegener granulomatosis.<sup>[3]</sup>

**METHODOLOGY:****CASE PRESENTATION:**

A Male subject, aged 72 years, retired, living in Samara Nagar, Amravati city, Maharashtra, with the chief complaints – Right eye Pain,

Swelling, Watering, Redness and Difficulty in opening the eyelids for 5-6 years. Patient gave history of Coronary artery bypass graft surgery (CABG) done 1 year back at Achyut Maharaj Heart Hospital, Amravati. He has been prescribed medicines for HTN for 1 year and taking the medication regularly. He consulted Netra Roga OPD department of Shalakyatantra, G.N.T Hospital, Amravati for further treatment.



### FINDINGS ON EXAMINATION:

#### Right eye-

- 1) Congestion
- 2) Lid oedema +ve (involving upper and lower both eye lids)
- 3) Mild pain on pressing the lid
- 4) Sticky discharge seen (mucoid)
- 5) On fluorescein staining- Cornea not stained

Left eye- WNL

Patient had using Spectacles of Power-

RE: -0.50 -1.00\*90

LE: +0.75 -1.25\*110

AR readings of the patient- RE: -0.50 -1.25\*76

LE: +0.50 -1.25\*107

#### Vision:

	Right eye	Left eye
V/A	6/18p	6/18
P/H	6/9p	6/9
N/V	N/12	N/36

#### Vision with specs:

	Right eye	Left eye
V/A	6/9p	6/9p
N/V	N/10	N/10

#### TREATMENT PROTOCOL:

Patient was advised Haridradi Bidalaka for 5 days.

On the basis of clinical signs and symptoms, the patient was diagnosed with NSOI with Kaphaj Netrabishyanda and advised Haridradi Bidalaka for 5 days using Haridra and Madhu.

**PREPARATION OF BIDALAKA:** Bidalaka paste was prepared with Haridra Churna and Madhu. **PROCEDURE OF APPLICATION-**

#### Poorva karma-

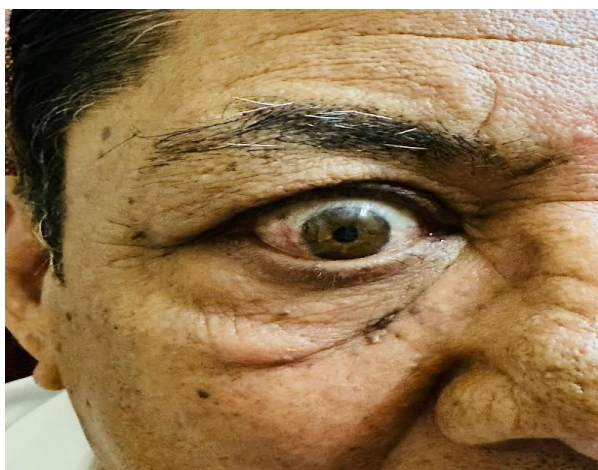
- (A) Wash hands with water.
- (B) Clean both the eyes and the surroundings with wet gauze pieces. **Pradhan Karma-**
  - (A) The patient is given a supine position with closed eyes.
  - (B) Haridradi Paste is applied under aseptic precaution around Right eye and eyelids except lid margins.
  - (C) According to Acharya Charaka, the thickness of Bidalaka should be equal to one-third of the thickness of thumb.

#### Paschat karma-

- (A) The eye is cleaned out with gauze piece before it dries up.
- (B) The patient is asked to wash and clean the face with Lukewarm water.

Patient was also advised to do a CT Orbit for further diagnosis, but He was unwilling to do so.

**RESULT:** On the day of follow up 5 days after the initial treatment, Patient was completely satisfied with the treatment and happy. He recorded almost 90% relief in his symptoms.



### ON EXAMINATION:

- 1) Right eye Minimal Swelling was visible
- 2) Swelling present only at upper lid
- 3) Lower lid swelling was completely resolved
- 4) Patient was able to easily open his Right eye without any pain.

Patient was advised to continue instillation of Topical antibiotic drops (Moxifloxacin 0.5% w/v) for 15 more days. He was also advised to visit the hospital in case of any aggravation of the old symptoms or appearance of new ones.

### DISCUSSION:

The prognosis for orbital pseudotumor varies greatly based on each patient's unique features, the severity of the disease, and the patient's reaction to therapy. While many patients with proper care have positive outcomes, others may encounter complications like diplopia, corneal exposure, optic nerve compression, and disease recurrence. These cases highlight the significance of close monitoring and multidisciplinary care in achieving the best possible long-term visual and functional outcomes [4]. The volatile oils and curcumin of *Curcuma longa* exhibit potent anti-inflammatory effects. Oral administration of curcumin in instances of acute inflammation was found to be as effective as cortisone or phenylbutazone, and one-half as effective in

cases of chronic inflammation. In rats with Freund's adjuvant-induced arthritis, oral administration of *Curcuma longa* significantly reduced inflammatory swelling compared to controls. In monkeys, curcumin inhibited neutrophil aggregation associated with inflammation. *C. longa*'s anti-inflammatory properties may be attributed to its ability to inhibit both biosynthesis of inflammatory prostaglandins from arachidonic acid, and neutrophil function during inflammatory states. Curcumin may also be applied topically to counteract inflammation and irritation associated with inflammatory skin conditions and allergies, although care must be used to prevent staining of clothing from the yellow pigment.[5]

### CONCLUSION:

Ayurvedic approach in treating Non-Specific Orbital Inflammation is effective and satisfactory. Symptomatic treatment should be the first line of treatment with further investigations such as CT Orbit done in order to reach a definite diagnosis.

### REFERENCES:

1. F. Salmon, J. (2019) Kanski's Clinical Ophthalmology. 9th Edition, Elsevier, Amsterdam. Non-Infective Inflammatory Disease, Page no. – 126-127
2. [https://eyewiki.aao.org/Nonspecific\\_Orbital\\_Inflammation\\_\(Idiopathic\\_Orbital\\_Inflammation,\\_Orbital\\_Inflammatory\\_Syndrome,\\_Orbital\\_Pseudotumor\)#Clinical\\_Presentation](https://eyewiki.aao.org/Nonspecific_Orbital_Inflammation_(Idiopathic_Orbital_Inflammation,_Orbital_Inflammatory_Syndrome,_Orbital_Pseudotumor)#Clinical_Presentation)
3. F. Salmon, J. (2019) Kanski's Clinical Ophthalmology. 9th Edition, Elsevier, Amsterdam. Non-Infective Inflammatory Disease, Page no. –127
4. Ronquillo Y, Zeppieri M, Patel BC. Nonspecific Orbital Inflammation. [Updated 2024 May5]. In: StatPearls [Internet]. Treasure Island (FL): StatPearls Publishing; 2024 Jan-. Available

from:

<https://www.ncbi.nlm.nih.gov/books/NBK551576/>

5. Shreedevi H. Huddar, E. Anupkumar, Anil

Jadhav, Classical review of Haridra (Curcuma longa). J Ayu Int Med Sci. 2023;8(4):122-127.

Available

From

<https://jaims.in/jaims/article/view/2409>

**Source of Support: None declared**

**Conflict of interest: Nil**

© 2024 IJIM (International Journal of Indian Medicine) |

An Official Publication of ARCA- AYURVEDA RESEARCH & CAREER ACADEMY

Website: [www.ijim.co.in](http://www.ijim.co.in) Email: [ijimjournal1@gmail.com](mailto:ijimjournal1@gmail.com)